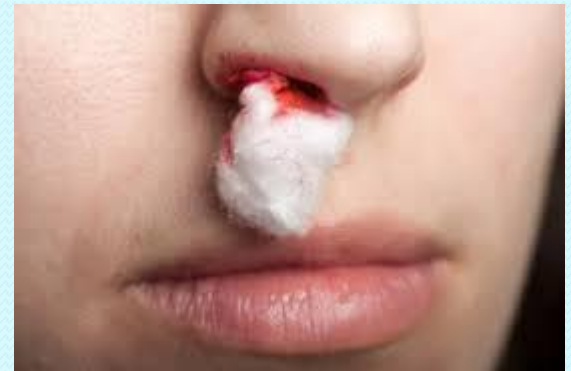
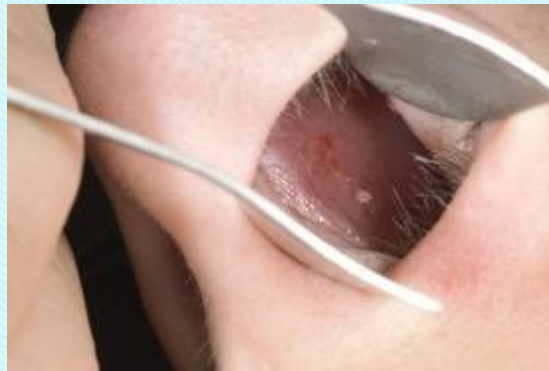
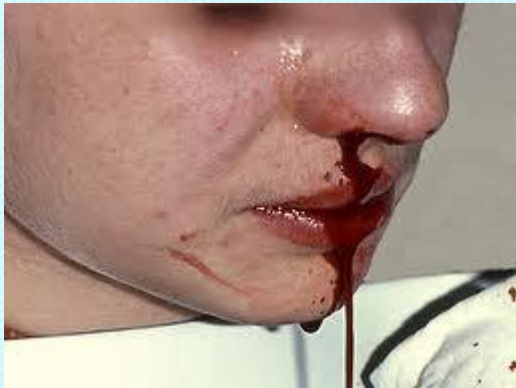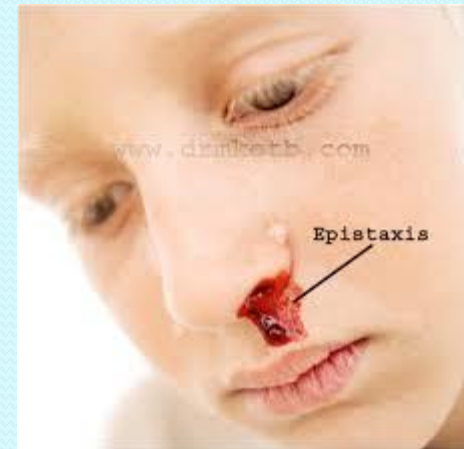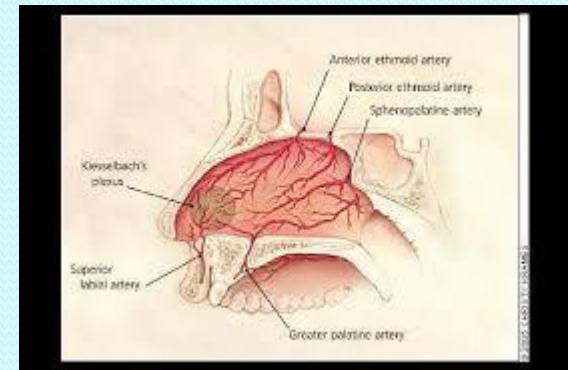
epistaxis

Bleeding from the nose



epistaxis

- Etiology
- 1- local causes
- 2- general causes

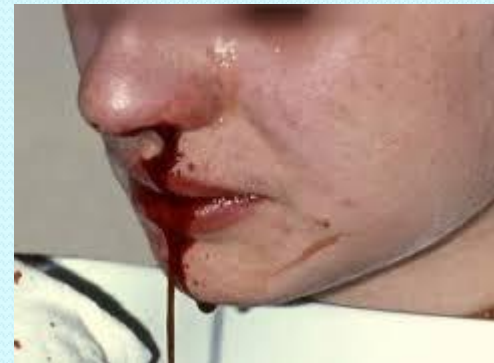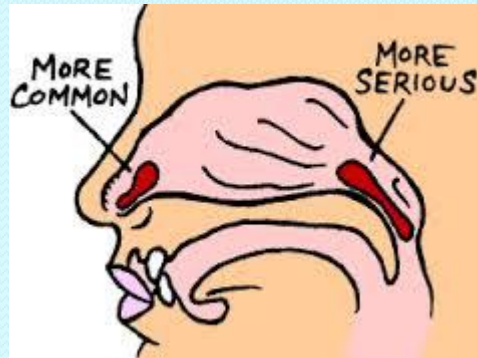


Epistaxis

- **I- Local causes:** 1- idiopathic
2- traumatic
- 3- neoplastic 4- DS
- **II- General causes:** 1- arterial hypertension
- 2- venous hypertension
- 3- blood diseases 4- bl. Vessel diseases
- 5- vitamin deficiency 6- drugs
- 7- hormonal

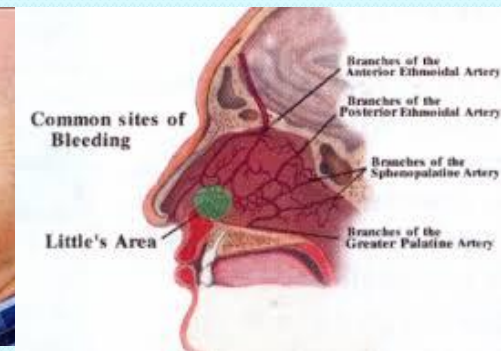
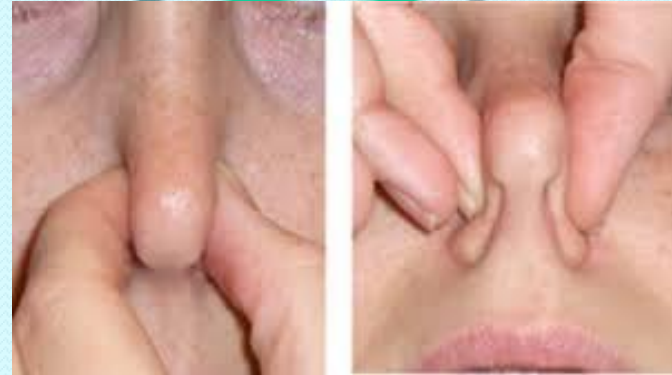epistaxis

- Clinical picture
- Mild or severe
- Anterior or posterior



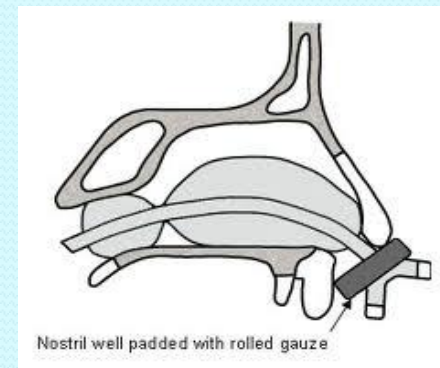
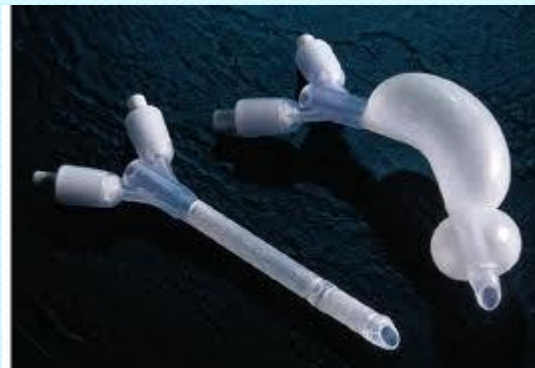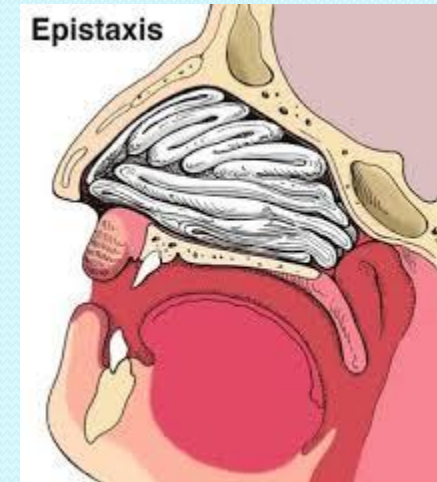
Epistaxis

- Management
- Mild cases
- 1- first aid
- 2- curative treatment



Epistaxis

- **Severe cases**
- 1- shock management
- 2- anterior + posterior packs
- 3- ligation + embolization
- Find cause

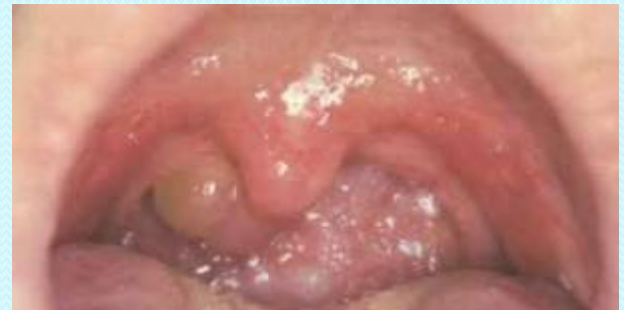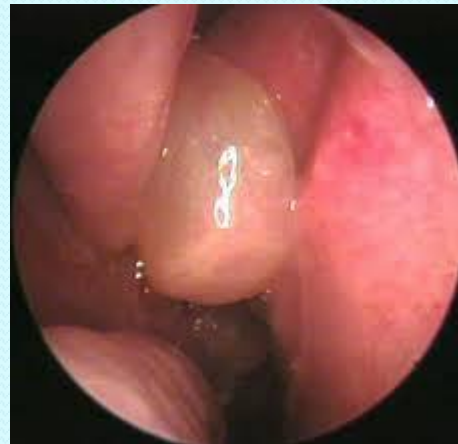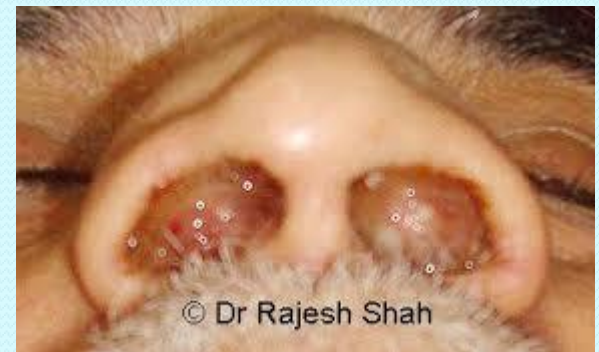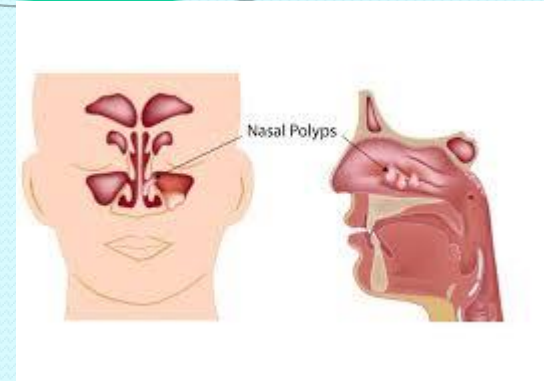


Nasal polyps

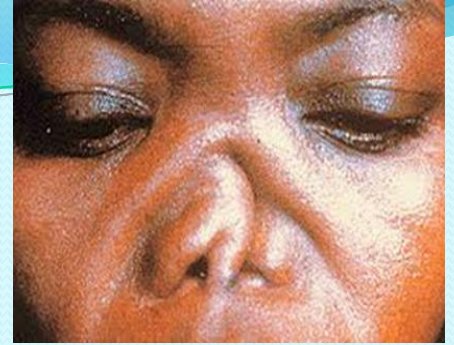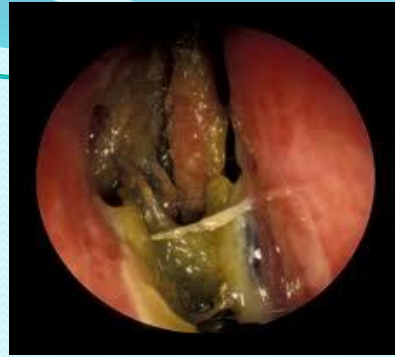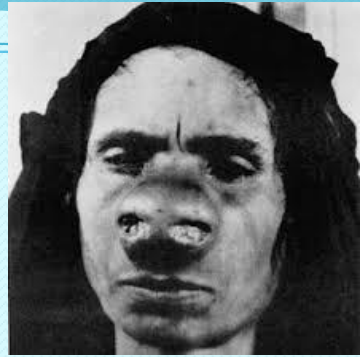- Pedunculated edematous mucosa
- **Types:**
- Allergic – inflammatory – mixed – neoplastic
- **Sites:**
- Ethmoidal – antral – septal

Nasal polyps

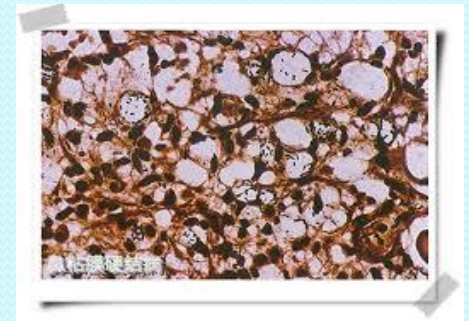
- **Treatment:** polypectomy
- **Antrochoanal polyp**
- **Maxillary sinus polyp**
- **Grows toward choana**



Scleroma

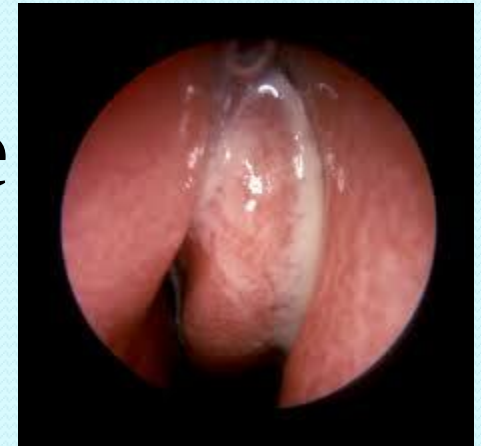
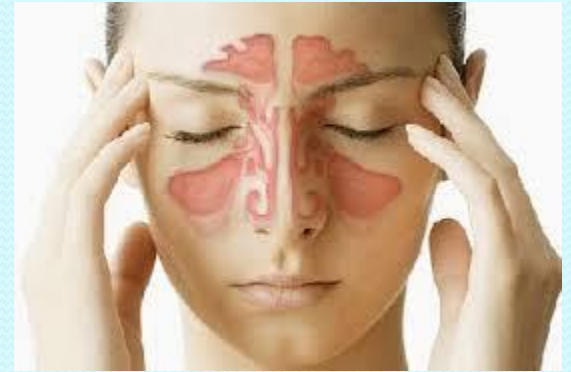
- Endemic disease in Egypt
- *Bacillus rhinoscleromatous*
- Clinical picture
- Atrophic – hypertrophic fibrotic
- Mikulicz cells – Russell bodies



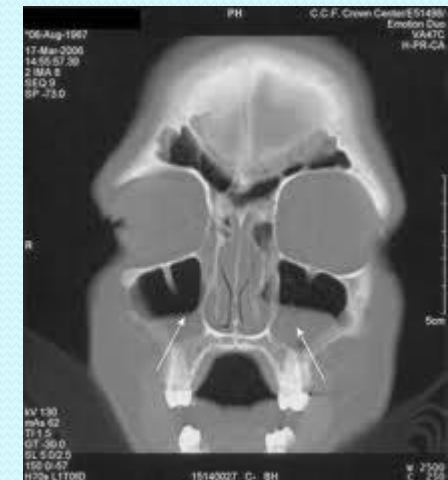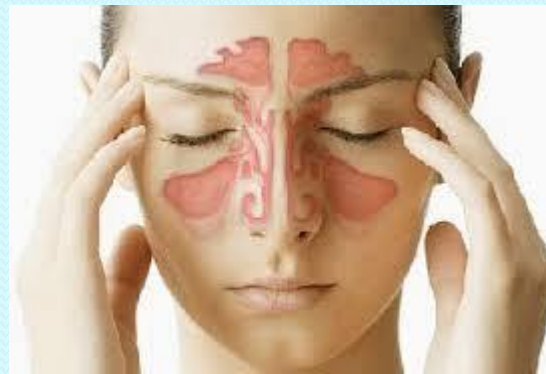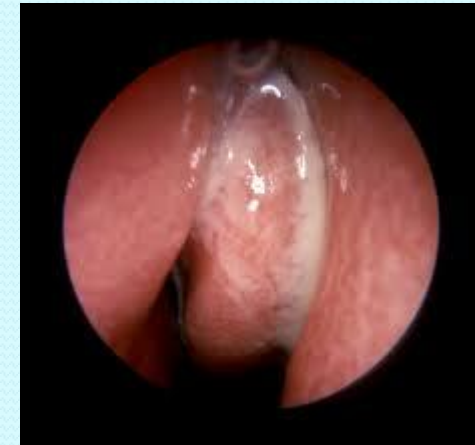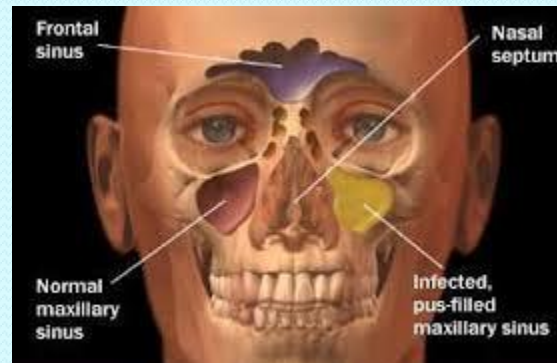
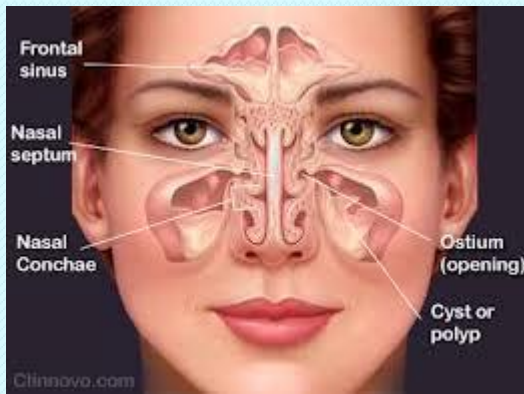
Sinusitis

- Acute – chronic
- **Acute sinusitis**
- Due to nasal or dental causes + fracture
- **C/P:** pain and headache
tenderness + pus
- **Investigations:** C.T



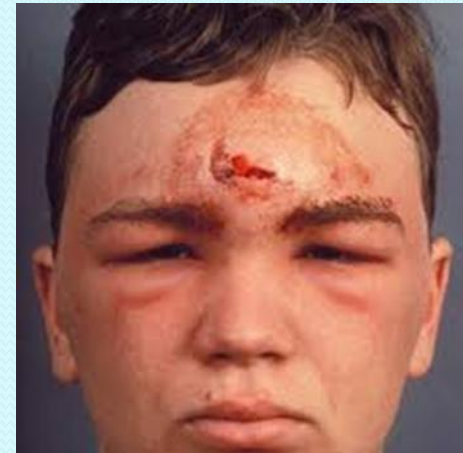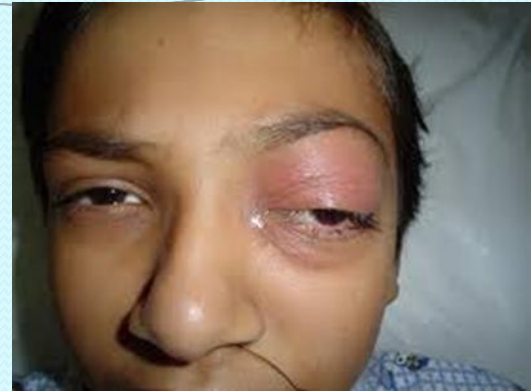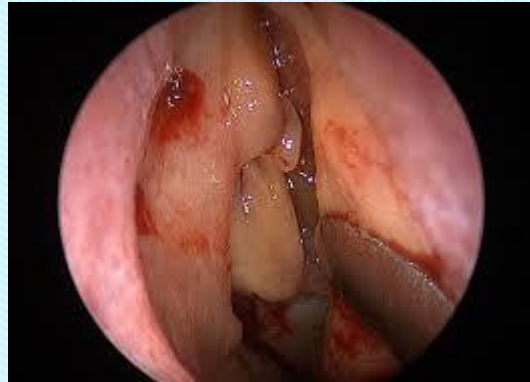sinusitis

- 1- Acute: Treatment

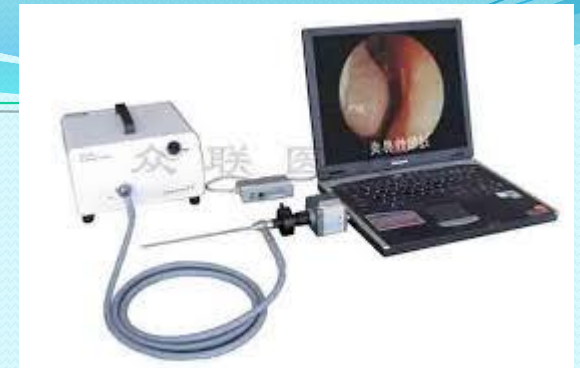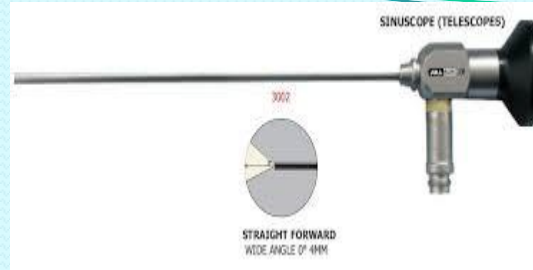


sinusitis

- **II- chronic**
- recurrent acute attacks
- **C/P:** Pain + headache, descending infections and septic focus
- Treat predisposing factory + FESS
- **Complications:**
- **Cranial – extra cranial – intra cranial**



sinoscopy



- Nasal visualization by fibroptic Sino scope
- 3 parts: lens, cable and light source
- Uses: diagnostic + operative
- Sterilize by cidex + autoclave